

**MASTER CASE PRESENTATION**

Effects of contrast cryolipolysis on flank region adiposity: Case study

Patrícia Froes Meyer PhD^{1,2} | Márcia Cristina Dias Consulin MSc³ | Thais Rodrigues PT⁴ | Aline Marques Pereira PT⁵ | Patrícia Carolina Martinez Lopes PT⁶ | Rodrigo Marcel Valentim da Silva MSc^{1,6,7} | Liliane Santos de Vasconcellos MSc¹

¹Federal University of Rio Grande do Norte, Natal, Brazil

²Potiguar University-UNP, Natal, Brazil

³University of Piracicaba – UNIMEP, Piracicaba, Brazil

⁴Centro Universitário Amparense – UNIFIA, Amparo, Brazil

⁵Gama Filho University- UGF, Rio de Janeiro, Brazil

⁶Estácio de Sá University, Rio de Janeiro, Brazil

⁷Maurício de Nassau University, Natal, Brazil

Correspondence

Patrícia Froes Meyer, Federal University of Rio Grande do Norte, Natal, Brazil.
Email: patricia.froesmeyer@gmail.com

Summary

Background: The Contrast Cryolipolysis is a non-invasive technique that aims to reduce localized adiposity with its heating-cooling-heating method, resulting in a 45% fat loss in the treated area, with no damage to the skin.

Objective: To investigate the effects of contrast cryolipolysis compared to conventional cryolipolysis on localized adiposity.

Materials and Methods: This is a case study was carried out with two volunteers. The circumference, ultrasonography, and the anthropometric characteristics' analyses of volunteers were performed before and after the intervention. The right flank region underwent conventional cryolipolysis, and the left flank underwent contrast cryolipolysis.

Results: The procedures performed in both volunteers had positive results. However, the use of Contrast Cryolipolysis promoted greater loss of adipose tissue, reducing perimeter and circumference measurements, as well as the adipose tissue thickness, acknowledged via ultrasonography.

Conclusion: The contrast cryolipolysis promotes greater localized adiposity reduction than the conventional cryolipolysis.

KEYWORDS

adiposity, body mass, contrast cryolipolysis, cryolipolysis

1 | INTRODUCTION

The cryolipolysis is a non-invasive method of fat layer reduction, which significantly decreases the fat layer thickness with no damage to the skin or other surrounding tissues.¹

Recently, the esthetic industry has developed a new method, the contrast cryolipolysis. The cryolipolysis is a non-surgical procedure that promotes localized adiposity reduction, presenting high patient and physician satisfaction indexes.²

The lipolysis occurs through a mechanism of adipocyte crystallization associated with a local inflammatory response. This inflammation triggers a mechanism of progressive and continuous fat cells

destruction with the rupture of the cells' membranes through the induction of a cellular apoptosis mechanism. Another mechanism that is modified by the cooling is the fat cell metabolic activity, inducing hormonal and biochemical adaptations that favor the metabolization of the fat reserves present in the tissue.^{3,4}

The contrast cryolipolysis allows a reduction of the discomfort generated by the low temperatures produced by the conventional method, considering it promotes lower irritability of nerve endings. In contrast, the heating promotes a blood flow increase that favors reperfusion, modulating the inflammatory response in adipose tissue after cryolipolysis.^{5,6} Therefore, the objective of this study was to

investigate the effects of contrast cryolipolysis compared to conventional cryolipolysis on localized adiposity.

2 | MATERIALS AND METHODS

2.1 | Drawing of study

This case study was approved by the Research Ethics Committee of the Federal University of Rio Grande do Norte—UFRN, under registration number 2.326.871. Two volunteers were selected, one male (volunteer 1) and one female (volunteer 2). Inclusion criteria were: presence of localized adiposity in the flanks, with a minimum fold of 2.0 cm and no history of anterior esthetic treatment in the region. Exclusion criteria were: previous esthetic and/or surgical procedures in the flanks, positive rheumatoid factor, rheumatoid arthritis, cryoglobulinemia, cold paroxysmal hemoglobinuria, Sjogren's syndrome, systemic lupus erythematosus, peripheral circulatory commitment, Reynaud's disease, hepatitis C, autoimmune disease, acquired immunodeficiency syndrome (AIDS), cold urticaria, open or infected wounds, recent bleeding area, acute or chronic infections, pregnancy, lactation, scarring in the region, hernia in the region, dermatitis and eczema, post herpetic neuralgia, neoplasia or tumor, obesity, excessive visceral fat, hepatic steatosis, skin flaccidity after considerable weight loss, hypovitaminosis D, infertility drug treatment, use of steroids or corticosteroids, Cushing's syndrome.

2.2 | Experimental protocol evaluation

The volunteers underwent a previous evaluation immediately before and 8 weeks after the cirtometry and the photographs, and before and 11 weeks after the ultrasonography. In the physical therapy evaluation, body mass (kg) and cirtometry (cm) were measured at umbilical scar level, 5 cm above and 5 cm below.⁷ All evaluations were performed by a single individual, who was responsible for the photograph, body weight, and perimetry evaluations, before and after the applications. The medical evaluation was performed by ultrasonography, the examination was performed with a high-resolution multifrequency transducer (5-12 MHz) GE Logiq P7 USA, in panoramic image, to visualize subcutaneous thickness from the anterior to the posterior sciatic spine.

2.3 | Procedure

The volunteers underwent a single application protocol on each flank, which consisted of the cryolipolysis technique and its variations, with HTM Electronics' Beauty Shape equipment (Registered with ANVISA (Brazilian Health Surveillance Agency) under number 80212480025).

Before the initial intervention, an assessment of body weight, perimetry, cirtometry, and ultrasonography measuring was performed. In addition to the analysis of the measurement of the adipose tissue thickness of the, a fat percentage loss analysis was

made. An analysis of the percentage difference between the first and second measurements was also performed, to find a loss percentage value.

Volunteer 1 received contrast cryolipolysis session on the right side, with initial heating application (40°C for 5 min), followed by a low-temperature positive cooling (8°C for 30 minutes) and by another heating application (38°C for 10 min).^{2,5} Then, the left side flank underwent a Conventional cryolipolysis session, which consists of the cooling with negative temperature at -7°C for 60 minutes.⁷ Only on the left side flank, upon session end, the volunteer received a vigorous massage in the region for 3 minutes to facilitate blood reperfusion. Volunteer 2 underwent contrast cryolipolysis on the right-side flank, with initial heating (40°C for 5 minutes), followed by low-temperature positive cooling (8°C for 30 minutes) and heating (38°C for 10 minutes). The left side flank received contrast cryolipolysis with initial heating (40°C for 5 minutes), followed by a low negative cooling application (-7°C for 60 minutes) then heating (38°C for 10 minutes).

2.4 | Treatment sequence

- With the patient in a standing position, demarcation of the anatomical regions of treatment (Right flank and Left flank) was made with a dermatographic pen. The flank: the region between the anterior and posterior axillary line of the sixth intercostal to the iliac crest.
- With the patient lying in right lateral decubitus, the region was protected with an antifreeze membrane.
- The medium-sized applicator was selected, (250 mL volumetric capacity).
- The applicator was positioned in the region to be treated with vacuum suction onset to 70 KPA, decreasing to 30 KPA after the skin fold was adjusted to the applicator.
- The blanket was inspected to check for any bendings or irregularities.
- The experimental protocol was performed.
- The applicator and the antifreeze membrane were removed.
- A manual massage was made on the treated spot (3 minutes).

After the procedure, the patients were reassessed under the initial evaluation criteria.

3 | RESULTS AND DISCUSSION

Volunteers 1 and 2 had a reduction in total body mass. Volunteer 1 reduced 3.3 kg, and volunteer 2 reduced 1.5 kg. Measurements of the cirtometry reduced from 3 to 6 cm, with the umbilical scar as reference (Table 1). Tables 3 and 4 describe the cirtometry and ultrasonography of the adipose tissue thickness.

It was observed that the procedures performed in both volunteers had positive results, with Volunteer 1 presenting 58% mean total reduction of right side subcutaneous thickness voluntary 2 with

TABLE 1 Result of perimetry before and after intervention, and body mass of volunteers

	Volunteer 1 before	Volunteer 1 after	Volunteer 2 before	Volunteer 2 after
5 cm above the umbilical scar (cm)	97.5	93.0	76.0	70.0
Umbilical scar (cm)	103.5	98.2	89.0	79.0
5 cm above the umbilical scar (cm)	104.0	101.0	94.0	90.0
Body mass (kg)	96.3	93.0	61.0	59.5

TABLE 3 Results of cirtometry before and after intervention

Adipose tissue thickness	Volunteer 1 before	Volunteer 1 after	Volunteer 2 before	Volunteer 2 after
Measure 1 (cm)	1.77	1.45	1.35	1.08
Measure 2 (cm)	5.11	1.58	2.26	1.05
Measure 3 (cm)	4.06	2.42	2.20	2.02

TABLE 4 Percentage of adipose loss before and after treatment

Percentage of loss	Volunteer 1	Volunteer 2
Left side (%)	56	28.5
Right side (%)	58	50

a 50% reduction. On the left side, there were also reductions of 56% and 28.5%, respectively (Table 4).

Figures 1 and 2 show the ultrasonography comparisons of before and after right-sided treatment of both volunteers.

During the research, it was possible to observe changes on the individuals weight, waist circumference, and subcutaneous thickness decrease, with changes in the contour of the treated region. In the

data analysis, the total body mass change occurred, but it was not considered a clinical transformation, since the cryolipolysis process is local and does not interfere with this variable and this result corroborates with other studies.^{1,6,8} It is probable that weight reduction may have interfered with localized fat loss and contributed to a reduction in total body mass.

Ferraro et al and Zelickson et al,^{1,6} in their studies with cryolipolysis, obtained positive results, with mentioned reduction of waist circumference. A similar result occurred in this study, in which the volunteers obtained reduction of the measurements varying from 3 to 6 cm difference after treatment. The ultrasonography could quantify the percentage of fat loss. Zelickson,¹ in this investigation, also performed an ultrasonographical analysis and observed a reduction of the fat layer after cryolipolysis application.⁹ The results of percent loss, cirtometry, perimetry, ultrasonography and measures of circumference and body mass showed greater reduction in volunteer 1 when compared to the values from volunteer 2. The difference in body composition, besides other factors such as physical activity, age, diet, and metabolism⁶ could reinforce such results.

Contrast cryolipolysis promotes blood reperfusion after the cooling application phase⁴. This response probably favors a regulation of the local inflammatory response, contributing to an increase in lipolysis, which is a possible factor for the greater adipose tissue loss, as seen in these works. Other methods that associate the cryolipolysis with radiofrequency or shock wave therapy have also promoted a response to reperfusion and modulation of the inflammatory response. However, contrast cryolipolysis promotes an immediate effect, which would accelerate the inflammatory response without the risk of cold caused by the cooling technique.^{10–12} Contrast cryolipolysis favors the lipolysis process through adipocyte crystallization, associated with a cellular lysis. This process consists of a complex network of metabolic reactions that reduce the quantity of

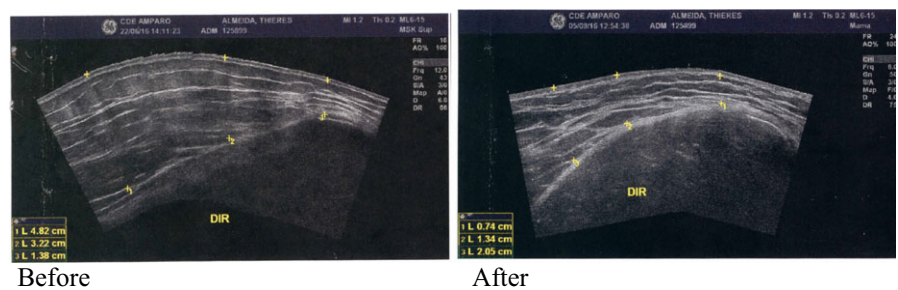
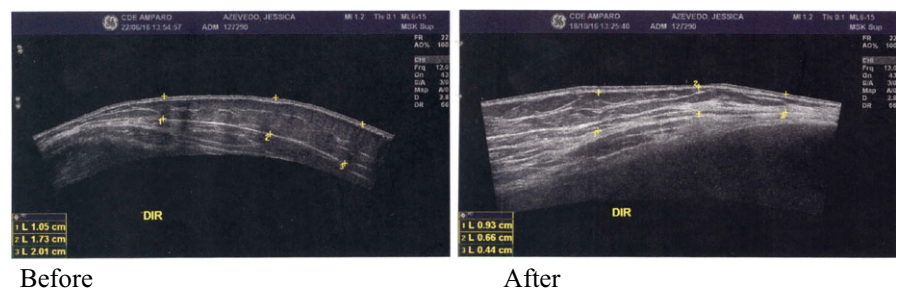
FIGURE 1 Comparison of ultrasonography before and after right-hand intervention—Volunteer 1**FIGURE 2** Comparison of ultrasonography before and after right-hand intervention—Volunteer 2

TABLE 2 Cirtometry results before and after intervention

Adipose tissue thickness	Volunteer 1 before	Volunteer 1 after	Volunteer 2 before	Volunteer 2 after
Measure 1 (cm)	4.82	2.05	1.05	0.93
Measure 2 (cm)	3.22	1.34	1.73	0.66
Measure 3 (cm)	1.38	0.74	2.01	0.44

fat cells, which clinically promotes a reduction in measurements and adipocyte volume.^{3,4,8,12}

The inflammatory response arises after tissue cooling, promoting a soft and progressive reduction of the adipose tissue and presenting fat volume reduction in the treated area, favoring the reduction of the anthropometric measures related to body constitution.^{13,14}

In this sense, the present investigation is relevant, even as a case study, by analyzing, through different methodologies, the clinical evolution of two patients submitted to contrast cryolipolysis treatment. Since there are few articles about it, it is hard to explain the results. More studies with more volunteers and more sessions are suggested.

Therefore, this study allowed of the adipose panniculus reduction, both with the use of conventional cryolipolysis and the contrast cryolipolysis in a single treatment session. A reduction in the concentration of adipose tissue occurred in the group who underwent the contrast technique. This result may be justified by the inflammatory modulation, which promotes fat concentration reduction.^{8,12}

ORCID

Patrícia Froes Meyer  <http://orcid.org/0000-0001-8530-8183>

REFERENCES

1. Zelickson BD, Burns AJ, Kilmer SL. Cryolipolysis for safe and effective inner thigh fat reduction. *Lasers Surg Med*. 2015;47(2):120-127.
2. Ingargiola MJ, Motakef S, Chung MT, Vasconez HC, Sasaki GH. Cryolipolysis for fat reduction and body contouring. *Plast Reconstr Surg*. 2015;135(6):1581-1590.

3. Pinto H. Local fat treatments: classification proposal. *Adipocyte*. 2016;5(1):22-26.
4. Pinto H, Ricart-Jane D, Pardina E. X-ray diffraction study confirms intra-adipocitary lipid crystallization after lipocryolysis stimulus. *Cryo Letters*. 2013;34(6):619-623.
5. Sasaki GH, Abelev N, Tevez-Ortiz A. Noninvasive selective cryolipolysis and reperfusion recovery for localized natural fat reduction and contouring. *Aesthet Surg J*. 2014;34(3):420-431.
6. Majdabadi A, Abazari M. Simulation of cryolipolysis as a novel method for noninvasive fat layer reduction. *Turk J Med Sci*. 2016; 46 (6):1682-1687.
7. Meyer PF, Furtado A, Araújo MS, Neto LG, Valentim da Silva RM, Queiroz C Effects of cryolipolysis on abdominal adiposity of women. *Cryo Letters*. 2017;38(5):379-386.
8. Meyer PF, da Silva R, Oliveira G, et al. Effects of cryolipolysis on abdominal adiposity. *Case Rep Dermatol Med*. 2016;2016(5):1-7.
9. Stevens WG, Bachelor EP. Cryolipolysis conformable-surface applicator for nonsurgical fat reduction in lateral thighs. *Aesthetic Surg J*. 2015;35(1):66-71.
10. Wahrlich V, Luiz E, Anjos A. Validação de equações de predição da taxa metabólica basal em mulheres residentes em Porto Alegre, RS, Brasil* Validation of predictive equations of basal metabolic rate of women living in Southern Brazil. *Rev Saúde Pública*. 2001;3935 (1):39-39.
11. Knobloch K, Kraemer R. Extracorporeal shock wave therapy (ESWT) for the treatment of cellulite—a current metaanalysis. *Int J Surg*. 2015;24:210-217.
12. Kim J, Kim DH, Ryu HJ. Clinical effectiveness of non-invasive selective cryolipolysis. *J Cosmet Laser Ther*. 2014;16(5):209-213.
13. Few J, Gold M, Sadick N. Prospective internally controlled blind reviewed clinical evaluation of cryolipolysis combined with multipolar radiofrequency and varipulse technology for enhanced subject results in circumferential fat reduction and skin laxity of the flanks. *J Drugs Dermatol*. 2016;15(11):1354-1358.
14. Pereira JX, Cavalcante Y, deOliveira RW The role of inflammation in adipocytolytic nonsurgical esthetic procedures for body contouring. *Clin Cosmet Investig Dermatol*. 2017;10: 57.

How to cite this article: Meyer PF, Consulin MCD, Rodrigues T, et al. Effects of contrast cryolipolysis on flank region adiposity: Case study. *J Cosmet Dermatol*. 2018;00:1–4. <https://doi.org/10.1111/jocd.12785>